

CASE STUDY

- 100% WOUND REDUCTION
- TOTAL HEALING IN 6 WEEKS
- 5 ACTIGRAFT APPLICATIONS

PATIENT:

83 year-old, male.

PAST MEDICAL HISTORY:

DM2, COPD, Chf, Ihf, Afib, HI, Chronic Venous Insufficiency, Dementia

LABS:

HA1C 6.6, H/H 13.2/40.2, MCV 85.5, Platelet 181

WOUND HISTORY:

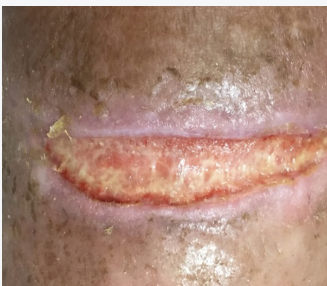- Right Posterior Calf Wound Categorized as a Pressure Ulcer
- 5 Week Old Ulcer
- 8.5 cm² X 0.06 cm, Moderate Serous Drainage

PAST TREATMENTS:

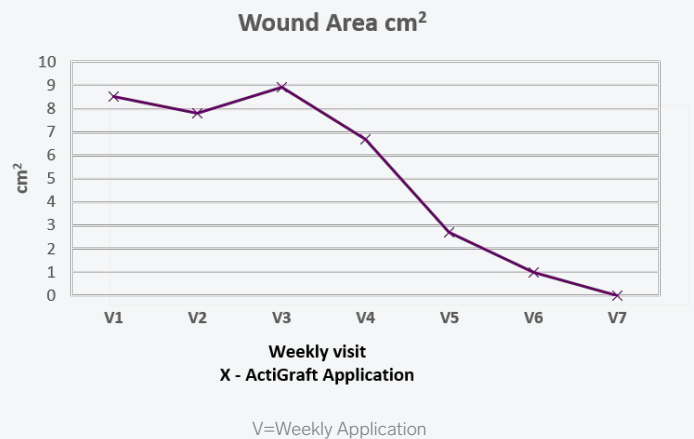
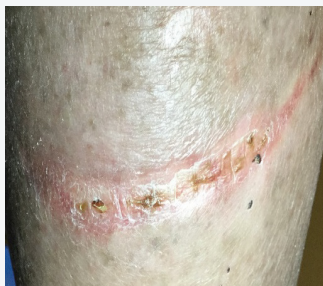Dakin's Saturated Gauze and Silver Alginate

ACTIGRAFT TREATMENT PROGRESSION:

Day 0



Day 84



OFFLOADING:

N/A